

# Percutaneous catheter drainage of a pyogenic lung abscess: A case report

G C Cupido, MD, FCP (SA), Cert ID (SA); G Günther, MD, MPH; L Elliston, BSc, MB ChB

Department of Internal Medicine, Faculty of Health Sciences, University of Namibia & Katutura Intermediate Hospital, Windhoek, Namibia

Corresponding author: L Elliston (lelliston@gmail.com)

Pyogenic lung abscesses represent a pathological entity with a high mortality rate if left untreated. Most patients respond well to intravenous antibiotics. Following the failure of conservative measures, invasive measures such as open-surgical procedures are required. Minimally-invasive options such as percutaneous catheter drainage of parenchymal lung abscesses, mainly if the respiratory reserve is limited or where the baseline functional status is poor, are also considered viable options. Pyogenic lung abscesses are necrotic cavitary lesions of the lung parenchyma and are often considered to be in the spectrum of anaerobic pleuropulmonary diseases. In this case report, we report on a 33-year-old female who presented with a 3-week history of cough, increasing breathlessness and right-sided pleurisy. She was diagnosed with pyogenic lung abscess and started on intravenous antibiotics. The abscess was drained using a pigtail catheter guided with a bedside ultrasonography.

**Keywords.** percutaneous catheter drainage; pyogenic lung abscess; resource-poor setting

*Afr J Thoracic Crit Care Med* 2022;28(1):33-34. <https://doi.org/10.7196/AJTCCM.2022.v28i1.145>

A 33-year-old woman presented to us with a 3-week history of cough, increasing breathlessness, fever and chills, anorexia and right-sided pleurisy. In the weeks before presentation, the coughing bouts had become increasingly violent and were associated with foul-smelling and copious purulent sputum production with a putrid taste in her mouth. The expectorations were positional. Two weeks before the onset of her respiratory complaints, she had a gynaecological intervention for a septic miscarriage – the intervention was carried out under conscious sedation. For the duration of her stay in the gynaecology wards, she had received intravenous antibiotics and had no further interventions. She developed what was labelled hospital-acquired pneumonia during her hospital stay post-intervention. She progressively deteriorated for the duration of her inpatient stay despite being on broad-spectrum antibiotics. The gynaecological team escalated her care to the high care unit in the maternity ward. After the apparent improvement in the unit, she was moved to a general gynaecology ward to continue with intravenous antibiotics. Her family eventually asked that she be discharged against medical advice because she had not improved satisfactorily.

The background history was unremarkable for periodontal disease, and she had no history to suggest reflux disease and had no background lung disease. She had no other medical or neurological comorbidities and denied the use of alcohol and had never smoked.

On presentation to medical emergencies, she was acutely ill, febrile with a temperature of 39.2°C, tachycardic with a heart rate of 125 beats per minute (bpm), saturating at 92% on room air, had normal dentition and no digital clubbing. The general examination was otherwise unremarkable. The respiratory examination revealed tachypnoea (she had a respiratory rate of 32 breaths per minute), decreased breath sounds on the right as well as a right-sided pleural rub. She was diagnosed with a pyogenic lung abscess (Fig. 1). She was admitted into the respiratory ward and started on intravenous antibiotics.

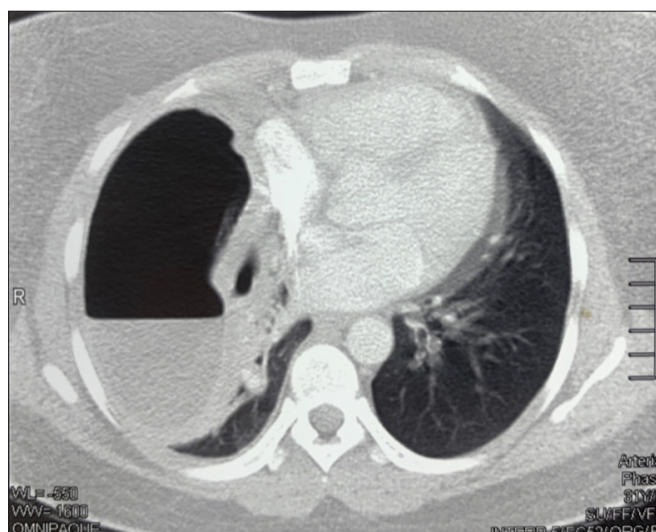


Fig. 1. Chest computed tomography (coronal view) showing large lung abscess with dependent air-fluid level.

There had been no satisfactory improvement in her clinical status despite appropriate conservative measures (including postural drainage and intravenous antibiotics). Sputum cultures identified *Klebsiella pneumoniae* sensitive to augmentin. She had been on antibiotics for 7 days but remained febrile and tachycardic (>120 bpm) and continued producing purulent sputum, with occasional streaks of blood. Consequently, we considered percutaneous catheter drainage because of nonresolution. We inserted (modified Seldinger technique) a 14F pigtail catheter with the aid of bedside ultrasonography aided by abscess anatomy that had been delineated by computed tomography (CT). Over 1 L of thick, foul-smelling yellow-green abscess material drained from the cavity on the first day. We further gently irrigated the

cavity with 5 - 10 mL of 0.9% saline solution daily until it cleared. The technique for percutaneous catheter drainage of pyogenic abscesses is well described in the literature.<sup>[1]</sup> The clinical condition of the patient improved within the next 72 hours, temperatures settled within 48 hours of drainage, while her heart rate normalised (to <90 bpm) after 72 hours. The patient remained in the ward for a further 7 days and was discharged in a stable condition.

## Discussion

Direct drainage is ideal as a principle of treatment of abscess disease and percutaneous catheter drainage has been reported as an option for the treatment of pyogenic lung abscess. However, it has not yet been established as a treatment method from the outset. In the past, pyogenic lung abscesses that were poorly responsive to conservative measures would have been managed surgically.<sup>[2]</sup> An update on percutaneous catheter drainage published in the *Annals of Thoracic Medicine* in 2012 found that the overall efficacy of percutaneous catheter drainage reached 84%, while the complication rate of the procedure was just >16%.<sup>[3]</sup> A more recent meta-analysis revealed that percutaneous catheter drainage was superior to conservative management in terms of total effectivity rate.<sup>[4]</sup> They found that the length of hospital stay was significantly shorter and the time to conversion to fever-free days was significantly shortened for the percutaneous catheter drainage group compared with patients treated with conservative measures. The authors further concluded that there was no significant difference in complication rates between the two groups.<sup>[4]</sup> A surgical series by Postma *et al.*<sup>[5]</sup> discussed dissatisfaction with open drainage of lung abscesses. They noted that there was a high mortality rate among patients who underwent surgical resection. Furthermore, they pointed out that the recovery was usually morbid. Other direct drainage techniques include endobronchial ultrasonography as well as CT-guided transthoracic drainage.<sup>[6,7,8]</sup>

## Conclusion

We recommend percutaneous catheter drainage as a viable treatment option for pyogenic lung abscess and as an alternative to already

established surgical interventions, particularly when the anatomical site of the lesion is favourable. Furthermore, in a resource-limited setting (and where access to surgical and anaesthetic expertise is limited), percutaneous catheter drainage would serve as a safe and effective substitute for more invasive surgical procedures in the appropriate clinical context.

**Declaration.** None.

**Acknowledgements.** None.

**Author contributions.** Equal contributions.

**Funding.** None

**Conflicts of interest.** None.

1. Prasad B, Shashirekha, Tewari SC, Kasthuri AS. Management of lung abscess with percutaneous catheter drainage. *Med J Armed Forces India* 1998;54(2):134-136. [https://doi.org/10.1016%2FS0377-1237\(17\)30503-8](https://doi.org/10.1016%2FS0377-1237(17)30503-8)
2. Shim C, Santos GH, Zelefsky M. Percutaneous drainage of lung abscess. *Lung* 1990;168(4):201-207. <https://doi.org/10.1007/BF02719693>
3. Wali SO. An update on the drainage of pyogenic lung abscesses. *Ann Thorac Med* 2012;7(1):3-7. <https://doi.org/10.4103/1817-1737.91552>
4. Lin Q, Jin M, Luo Y, Zhou M, Cai C. Efficacy and safety of percutaneous tube drainage in lung abscess: A systematic review and meta-analysis. *Expert Rev Respir Med* 2020;14(9):949-956. <https://doi.org/10.1080/17476348.2020.1770086>
5. Postma MH, le Roux BT. The place of external drainage in the management of lung abscess. *S Afr J Surg* 1986;24(4):156-158.
6. Yaguchi D, Ichikawa M, Inoue N, Kobayashi D, Shizu M, Imai N. Transbronchial drainage using endobronchial ultrasonography with guide sheath for lung abscess: A case report. *Medicine (Baltimore)* 2018;97(20):e10812. <https://doi.org/10.1097/md.00000000000010812>
7. Kelogrigoris M, Tsagouli P, Stathopoulos K, Tsagaridou I, Thanos L. CT-guided percutaneous drainage of lung abscesses: Review of 40 cases. *JBR-BTR* 2011;94(4):191-195. <https://doi.org/10.5334/jbr-btr.583>
8. Van Sonnenberg E, D'Agostino HB, Casola G, Wittich GR, Varney RR, Harker C. Lung abscess: CT-guided drainage. *Radiology* 1991;178(2):347-351. <https://doi.org/10.1148/radiology.178.2.1987590>

Accepted 8 February 2022.